

# Preliminary Results on the Syncrystallization Technique for Fixed Provisionalization of Immediately Loaded Implants: A Twelve Months Follow-up

Marco Degidi<sup>1</sup>, Peter Gehrke<sup>2</sup>, Andre Spanel<sup>3</sup>, Adriano Piattelli<sup>4</sup>

<sup>1</sup> Bologna/ Italy, <sup>2</sup> Ludwigshafen/ Germany, <sup>3</sup> Mannheim/ Germany, <sup>4</sup> Chieti/ Italy



## Purpose

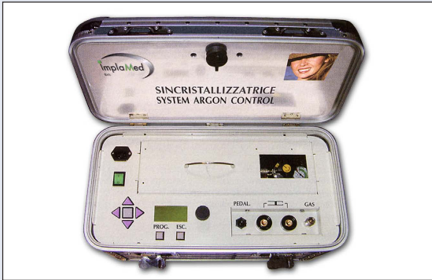A successful protocol for immediate loading of multiple implants depends on an adequate fixation and immobility of the implants in order to prevent the risk of micro-movements in relation to the surrounding bone. The objective of this article was to evaluate a prosthetic concept for an accelerated rigid splinting of multiple implants for same-day immediate loading with metal-reinforced provisional restorations using a novel technique of welding temporary implant abutments with a pre-fabricated titanium bar directly in the oral cavity (Syncrystallization).

## Materials and Methods

Between June 2004 and January 2005, immediate loading of threaded implants with a metal-reinforced, acrylic resin provisional restoration at stage one surgery was evaluated in 40 consecutive patients. A total of 192 implants were placed in selected edentulous or partially edentulous patients using the Syncrystallization technique. Once the titanium bar was welded intraorally to the abutments, opaque was applied and the provisional restoration was relined and screw-retained the same day. In addition, a comparison of deformations and stress distributions in implant-supported, metal-reinforced and non-metal-reinforced resin provisional restorations were analyzed in the edentulous mandible by a three-dimensional finite element model (FEM).

	N° Cases	N° Implants
Total Edentulous	14	103
Partially Edentulous	26	89
<b>Total</b>	<b>40</b>	<b>192</b>

Number of implants and cases according to partially and total edentulism



The Syncrystallization Unit

Implant	N°
FRIALIT®	16
XIVE®	112
XIVE® TG	13
Maestro™	14
Prodigy	14
ANKYLOS®	23
<b>Total</b>	<b>192</b>

Number of implant types inserted

## Results

All of the 192 rigidly temporized immediately loaded implants osseointegrated. An implant success rate of 100% was achieved over a period of six months post placement. No fracture or luting cement failure of the provisional restoration occurred during the observation time. Compared to mere acrylic superstructures, a significant reduction of deformation and strain within metal-reinforced provisional restorations was detected by FEM analysis.

## Discussion

Rigid temporization has been recognized to have a significant impact on the peri-implant tissue response in immediate implant loading since it reduces the mechanical stress exerted on each implant.

## Conclusion

The results of this study indicate that the Syncrystallization technique allows an expedite and adequate rigid splinting of multiple immediately loaded implants. The advantages of the new technique are:

- Reduction of treatment time for immediate temporization at stage one surgery
- Predictable fixation and immobility of implants in the early stages of bone healing
- Less time for repairing provisional restorations as a result of no or rare fracture.

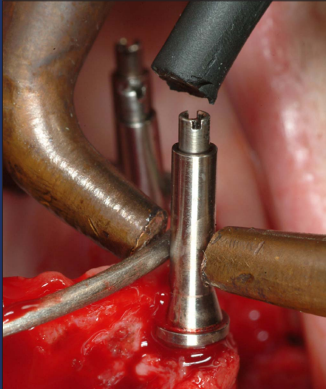

Fig. 1: The abutment and the titanium bar are pressed together by the welding clamp

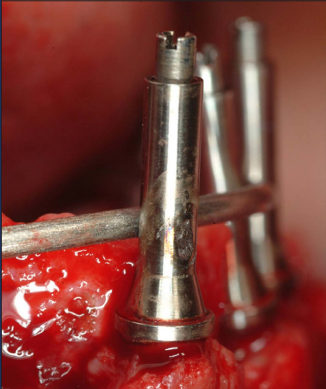


Fig. 2: The two components are welded

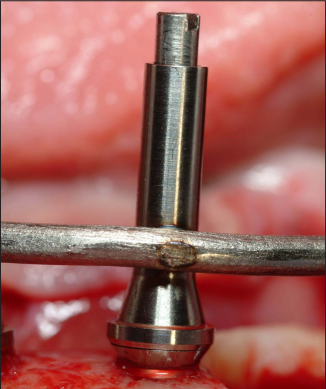


Fig. 3: The welding spot



Fig. 4: Cross section of a welding joint at 20-fold magnification. Temporary abutment (round section above) and titanium bar (straight section below)

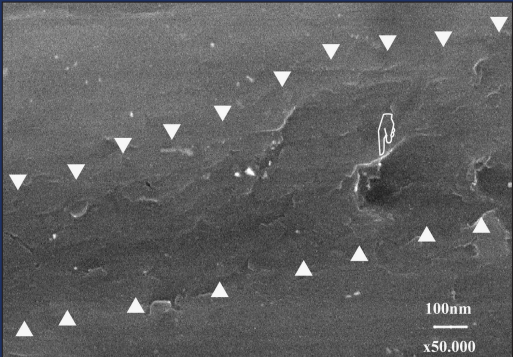


Fig. 5: Welding joint at 50,000-fold magnification. Only minor porosity can be detected

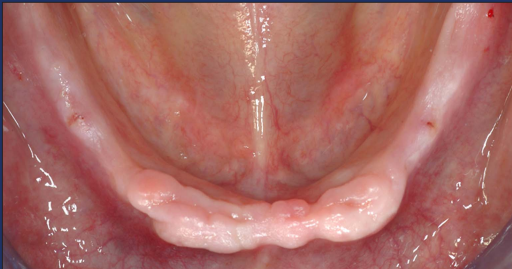

Fig. 6: Edentulous mandible

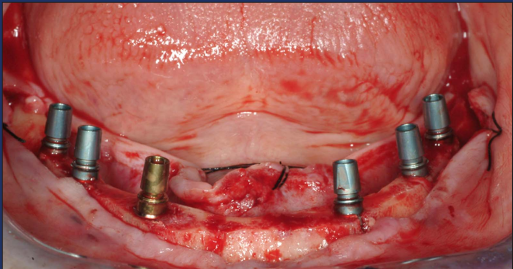


Fig. 7: Six implants placed (XIVE®)

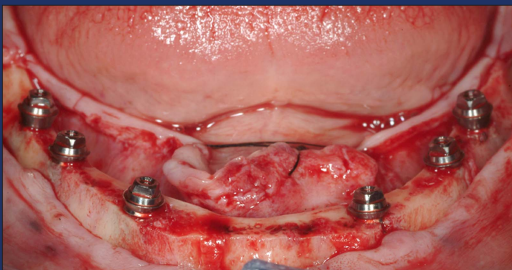


Fig. 8: MP abutments

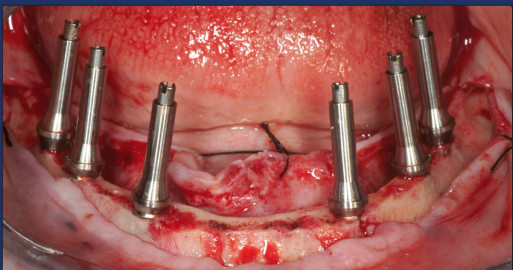


Fig. 9: Welding abutments

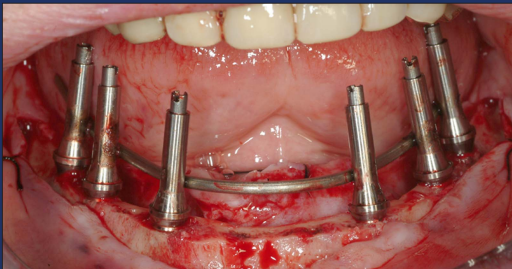


Fig. 10: Abutments connected by the intra orally welded bar

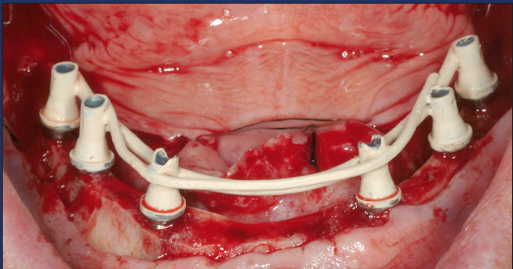


Fig. 11: Framework has been removed, cut, sandblasted, opaqued and replaced

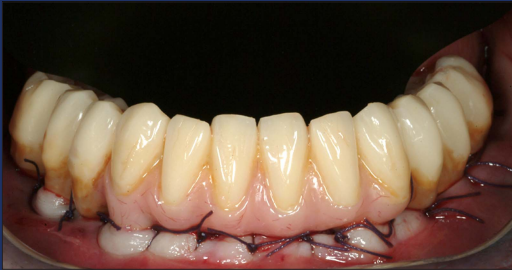

Fig. 12: Temporary relined over the framework, screw retained

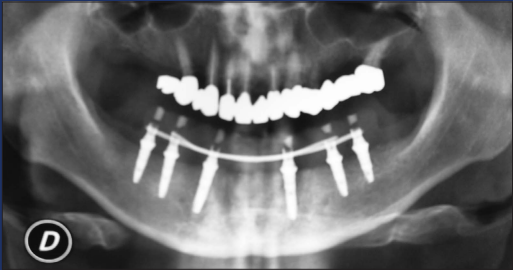

Fig. 13: Post op X-ray

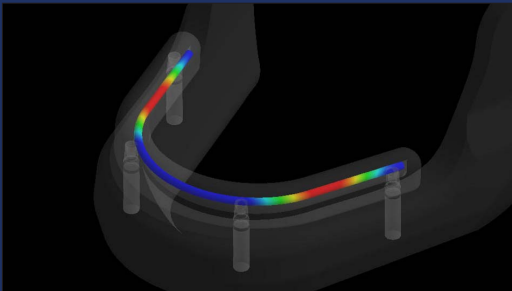
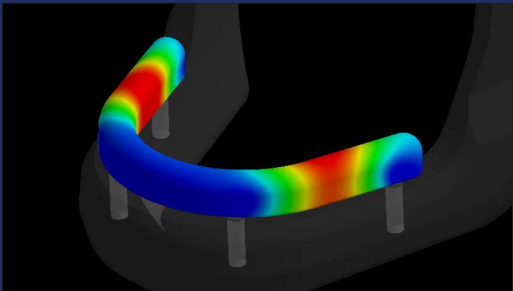


Fig. 14 a+b: Titanium-bar reinforced acrylic provisional restoration (FEM)



5<sup>th</sup> EUROPERIO, Madrid  
29, 30 June and 1 July 2006

Marco Degidi, MD, DDS  
Via Spina 12  
40139 Bologna, Italy  
E-mail: info@degidi.it